

**A Cone-Beam Computed Tomography Outcome Evaluation of Maxillary Posteriors
after Endodontic Microsurgery**

BY

LAUREN M. ALLEGRETTI

B.S., University of Illinois at Urbana-Champaign, 2010

D.D.S., University of Illinois at Chicago, College of Dentistry, 2014

THESIS

Submitted as partial fulfillment of the requirements
for the degree of Masters of Science in Oral Sciences
in the Graduate College of the
University of Illinois at Chicago, 2016

Chicago, Illinois

Thesis Committee:

Dr. Mohamed Fayad, Chair and Advisor

Dr. Bradford Johnson, Advisor

Dr. Xiaoxian Meng, Advisor

ACKNOWLEDGEMENTS

I would like to sincerely thank the members of my thesis committee, Dr. Mohamed Fayad, Dr. Bradford Johnson, and Dr. Xiaoxian Meng for their constant support and assistance. Without their advice, help, and support, this project would not have been possible.

TABLE OF CONTENTS

| <u>CHAPTER</u> | | <u>PAGE</u> |
|----------------|--|-------------|
| I. | INTRODUCTION..... | 1 |
| | A. Background..... | 1 |
| | B. Significance of the Study..... | 3 |
| | C. Specific Aims..... | 4 |
| | D. Hypothesis..... | 5 |
| II. | REVIEW OF THE LITERATURE..... | 6 |
| | A. Traditional Endodontic Surgery..... | 6 |
| | B. Mineral Trioxide Aggregate..... | 8 |
| | C. Contemporary Endodontic Surgery and Endodontic Microsurgery..... | 9 |
| | D. The Dental Operating Microscope..... | 11 |
| | E. Cone-Beam Computed Tomography..... | 11 |
| III. | MATERIALS & METHODS..... | 16 |
| | A. Study Design..... | 16 |
| | B. Evaluation of CBCT Scans..... | 17 |
| | C. Data Collection..... | 18 |
| IV. | STATISTICAL ANALYSIS..... | 21 |
| V. | RESULTS..... | 22 |
| VI. | DISCUSSION..... | 25 |
| VII. | CLINICAL RELEVANCE AND LIMITATIONS..... | 27 |
| VIII. | FUTURE RESEACH..... | 28 |
| IX. | CONCLUSIONS..... | 29 |
| X. | CITED LITERATURE..... | 30 |

LIST OF TABLES

| <u>TABLE</u> | | <u>PAGE</u> |
|--------------|--|-------------|
| I. | NON-SIGNIFICANT FACTORS..... | 22 |
| II. | PERCENTAGE HEALING BY TOOTH AND BY ROOT..... | 23 |
| III. | HEALING VS. SINUS PERFORATION BY ROOT..... | 24 |
| IV. | COMBINED HEALED AND HEALING VS. SINUS PERFORATION..... | 24 |

LIST OF FIGURES

| <u>FIGURE</u> | | <u>PAGE</u> |
|---------------|---|-------------|
| FIGURE 1. | Sinus Perforation..... | 19 |
| FIGURE 2. | Healed Tooth #3 after Surgery with a Sinus Perforation..... | 20 |

LIST OF ABBREVIATIONS

| | |
|---------|--|
| CBCT | Cone-Beam Computed Tomography |
| CBCTPAI | Cone-Beam Computed Tomography Periapical Index |
| EBA | Ethoxy benzoic acid |
| IRM | Intermediate Restorative Material |
| MTA | Mineral Trioxide Aggregate |
| PAI | Periapical Index |

SUMMARY

Current methods of endodontic surgery (root-end surgery), which are collectively known as endodontic microsurgery, have greatly improved success rates of the procedure. However, the evaluation of healing after surgery has been confined mostly to periapical radiographs even with the advent of cone-beam computed tomography (CBCT) for pre-operative evaluation. Furthermore, healing after surgery in conjunction with proximity of the tooth roots to vital structures has yet to be evaluated.

The null hypothesis is that a perforation into the maxillary sinus during endodontic microsurgery on maxillary posterior teeth will not affect overall healing after surgery.

The inclusion criteria were cone-beam scans taken on maxillary posterior teeth with both pre-operative scans and post-operative recalls scans of high diagnostic value in all three dimensions, post-operative scans must be from at least six months after the date of surgery, and from patients aged 18 years or older with an endodontically treated tooth requiring apical surgery between January 1, 2011 and July 15, 2015. All scans were de-identified prior to examination and were relabeled by a unique code number. All CBCT scans were read using the computer software compatible with the scan, Carestream (Kodak Dental Systems, Atlanta, GA). The dates of the pre-operative and recall scans were recorded as were the age range and sex of the patient. The tooth, root, and presence or absence of sinus involvement were also recorded. Recall times ranged from six to thirty months post-operatively. There was a statistically significant difference ($p < 0.05$) between sinus involvement and no sinus involvement groups for

SUMMARY (CONTINUED)

healing but this difference was eliminated when the healed and healing groups were evaluated as one. Healing was unaffected by age and sex of the patient and the use of a bone graft during surgery.

In conclusion, overall healing of maxillary posterior teeth following endodontic microsurgery was unaffected by a sinus perforation during the surgical procedure. Therefore, the null hypothesis was rejected.

I. INTRODUCTION

A. Background

The goal of endodontic (root canal) therapy is the prevention or treatment of apical periodontitis. Success is dependent upon proper cleansing and shaping of the root canal system, followed by a three-dimensional obturation to hermetically seal and prevent infection/reinfection of the root canal system and a functional and satisfactory restoration (Ng 2008). Following unsuccessful endodontic treatment, the next step is often non-surgical retreatment or surgical retreatment. Surgery is often a more commonly presented option for anterior teeth compared to posterior teeth due to the additional complexities of tooth and facial anatomy in the posterior region. The goal of endodontic microsurgery is to create an effective barrier between the canal space and the apical tissues when creating one via orthograde treatment is not possible or the existing seal is suspected to be less than ideal.

Traditional endodontic surgery was done with no magnification or more recently with the aid of loupes. Resection of the root end was done on a bevel typically at an angle of 45 degrees. The retro-preparation, if done, was completed using burs in a surgical hand piece with a micro-head (Gutmann 2014). Retrograde filling materials were amalgam, intermediate restorative material, Retroplast, and burnished gutta-percha. These materials are not biocompatible and were prone to failure over time. The surgical technique allowed for leakage around the retrograde filling if one was placed (Dorn 1990).

The advent of modern endodontic surgical techniques began with the introduction of the dental operating microscope in the 1990s. The microscope provides both magnification and illumination allowing for improved visibility of the surgical site, especially the root end. With the microscope came smaller instruments specifically designed for microsurgery and new microsurgical techniques. One of these techniques is ultrasonic instrumentation of the root end, which was an important addition to endodontic microsurgery. The size and angulation of the surgical ultrasonic tip allow for root end resection at a minimal to zero degree bevel. This angle allows for a uniform three-millimeter deep root-end preparation and condensation of a root-end filling material (Gilheany 1994). The material of choice for root-end filling has also changed with modern techniques.

The uniform thickness of a biocompatible filling material prevents apical leakage and creates an environment where the periodontal ligament can reattach to both the tooth and the retrograde filling material. Modern surgical techniques have greatly increased the success rates of periapical surgery from 59% using traditional techniques to 94% using magnification and modern surgical techniques (Setzer 2010). Cone-beam computed tomography (CBCT) has recently become a common imaging modality for the assessment of dental and apical tissues prior to endodontic surgery (AAE 2015).

B. Significance of the study

Cone beam computed tomography has become the standard imaging modality pre-operatively for endodontic microsurgery in part to assess for the proximity to vital structures. However, CBCT has not been consistently used to evaluate healing on recall after surgery. Proximity of the maxillary sinus to posterior tooth roots can cause a sinus perforation during surgery, which may affect the overall healing following root-end surgery.

C. Specific Aims

The purpose of this retrospective study was to determine the outcome of endodontic microsurgery (root-end surgery) with or without sinus perforation during surgery, and more specifically, to evaluate the effect of a maxillary sinus perforation during surgery on healing time and overall healing.

D. Hypothesis

The following null hypothesis was tested:

Healing following endodontic microsurgery on maxillary posterior teeth is unaffected by a sinus perforation during the surgical procedure.

II. REVIEW OF THE LITERATURE

A. Traditional Endodontic Surgery

Traditional endodontic surgery has been around for hundreds of years. Accounts of the procedure of intentional replantation have been around since the eleventh century. There is documentation of root end resection and root amputation being done as early as the 1840s to the 1860s. Originally, root ends were simply flattened, burnished, or polished. Schuster was the first to encourage apical preparation of the root with a slot preparation in 1913, a technique that continued to be used until the advent of endodontic microsurgery in the 1990s. The introduction of instruments for use during traditional surgical procedures began with the miniature head hand piece in 1939 by Tangerud (Gutmann 2014).

Amalgam was the root-end filling material of choice along with intermediate restorative material (IRM) until the 1990s. At the time, amalgam provided the best seal and was the most biocompatible material available. Amalgam posed many problems such as leakage, corrosion, delayed expansion, amalgam tattooing of tissue, and ion release (Dorn 1990). In a study on the response of the periapical tissue to various root-end filling materials, amalgam was shown to have a significantly poorer tissue response compared to some of the modern options for root-end filling material with an average distance of 0.9mm to 1.6mm of space between the amalgam root-end filling and the regenerated bone (Baek 2010). In a study comparing IRM and current biocompatible retrograde filling materials, the study did not find any significant differences but the

data suggested that IRM did not perform as well as some current materials (Lindeboom 2005). The preparation for the amalgam was done using a micro-head hand piece.

Another method was simply burnishing the gutta-percha exposed after resection. Gutta-percha is more biocompatible than amalgam. However, burnished gutta-percha does not fill in a contaminated isthmus and would allow for persistent disease. Also, a study on the tissue response to various root-end filling materials showed that there was still moderate inflammation adjacent to the gutta-percha and that hard tissue did not reform in any sample adjacent to the gutta-percha retrograde filling (Walivaara 2012).

An alternative approach for sealing the resected root-end involved placement of a bonded filling material. Retroplast™ is a dentin-bonded resin composite that was used as a root-end filling in endodontic surgery. The technique involved creating a dome-shaped filling on the root-end to seal the canal. While Retroplast™ showed some success as a root-end filling, the combined success rate for complete and incomplete healing was 82%, which is still lower than reported success rates for endodontic microsurgery using current bioceramic and calcium silicate-type materials (Yazdi 2007).

Prior to completing the root-end preparation and filling, the root end must be resected. The original method of root-end resection required a steep bevel, often forty-five degrees or more, to allow for visualization of the resected surface. This angle was useful because small and micro instruments were not yet developed to be able to indirectly examine the root; however, the steep angle also contributed to surgical failure due to leakage along both the filling and the open resected dentinal tubules. In a study

looking at apical dentin permeability and microleakage, Gilheany (1994) compared zero-, 30- and 45- degree bevels. The results showed that there was a significant increase in leakage as the degree of the bevel increased. The Gilheany study also examined microleakage along retrograde fillings of varying depth and found that a thicker retrograde filling allowed for significantly less microleakage.

Traditional endodontic surgery was done for many years and did allow for greater tooth retention in a time when dental infection frequently led to extraction. However, success rates for traditional endodontic surgery were relatively poor. Traditional endodontic surgery is defined as a procedure with a beveled root-end resection, root-end preparation with a bur, and an amalgam root-end filling all done under minimal or no magnification. In a comparison study between endodontic microsurgery and traditional endodontic surgery, the success rate for the traditional approach was found to be 59% (Setzer 2010).

B. Mineral Trioxide Aggregate

One of the greatest achievements for improving the success rates of endodontic surgery is the development of biocompatible materials for root-end filling such as mineral trioxide aggregate, or MTA. This material was developed in the 1990s and it has been advocated for multiple uses in dentistry due to its biocompatibility. MTA was tested against gutta-percha, intermediate restorative material (IRM), and SuperEBA, and it was found that the only material that allowed for formation of hard tissue against the root-end filling was MTA (Walivaara 2012). The other materials tested all showed

increased distance between the material and the hard tissue compared to MTA and mild to moderate inflammation adjacent to the material (Walivaara 2012).

Another study compared MTA to IRM and while no significant differences were found, MTA showed more cases of complete healing and fewer failures at the one-year recall time compared to IRM (Lindeboom 2005). This study confirmed the findings of Chong (2003) showing that MTA appeared to perform better but the difference was not statistically significant. In a five-year follow-up study of patients who had endodontic surgery, there was a decrease in success at five-years post-operatively compared to one-year; however, this difference was less if MTA was used as the root-end filling material (von Arx 2012). There are also newer bioceramic materials available that can be used as root-end filling materials in place of MTA. These materials appear to be highly biocompatible as well and with further research may prove to be as good as mineral trioxide aggregate.

C. Contemporary Endodontic Surgery and Endodontic Microsurgery

Contemporary endodontic surgery and endodontic microsurgery are very similar as defined by Setzer. Both consist of the surgical procedure performed doing a root-end resection with minimal to no bevel, a retro-preparation using ultrasonic instruments, and the placement of a biocompatible root-end filling. The difference is endodontic microsurgery is done with the aid of the dental operating microscope or the endoscope and contemporary endodontic surgery is done with no magnification or loupes only (Setzer 2012).

As the microsurgical procedure developed, the armamentarium to perform surgery changed. The retrograde filling material shifted from amalgam to more biocompatible materials like MTA as discussed earlier. Smaller instruments such as the micro-mirror and surgical ultrasonic tips were also introduced to allow for visualization of the resected root-end under magnification with a zero-degree bevel in a smaller osteotomy. Initially, it was thought that ultrasonic preparation of the root-end might result in the formation of cracks on the root walls (Abedi 1995). However, further studies showed that there was no significant difference in alteration of the root after resection or after ultrasonic preparation (Belting 1997). This finding was confirmed by Waplinton (1997) who showed that ultrasonic instrumentation of the root end did not cause any cracking of the root surface on any ultrasonic power setting.

The development of ultrasonic instruments, biocompatible root-end filling materials, and microsurgical instruments allowing for a zero-degree angle of resection improved success rates of endodontic surgery from 59% for traditional methods to 94% for endodontic microsurgery (Setzer 2010). While all of these developments together significantly increased the success rate of endodontic surgery, some are more important than others.

The use and benefit of ultrasonics for apical surgery was compared to the traditional protocol of root-end preparation with a bur. In a clinical study with a recall time of approximately fourteen months, the authors found that the use of the ultrasonics improved the outcome of surgery and the outcome was significantly better in molar teeth when ultrasonics were used compared to preparation with a bur

(deLange 2007). Setzer examined the significance of magnification on success rates of surgery. He compared contemporary endodontic surgery using microsurgical techniques and loupes or no magnification to endodontic microsurgery using microsurgical techniques and the dental operating microscope or the endoscope and found that the success rate for contemporary surgery was 88% compared with 93.5% for endodontic microsurgery (2012).

D. The Dental Operating Microscope

Surgical microscopy has been used in many fields for decades. It originated in the fields of neurosurgery and ophthalmology. In the 1990s, the surgical microscope was adapted to dental needs and the dental operating microscope was developed. Perrin (2014) completed a visualization study showing that the dental operating microscope allows for measurably better vision inside the root canal and was the only method to effectively visualize the inside of the canal. The dental operating microscope has the advantages of both magnification and illumination.

E. Cone-Beam Computed Tomography

Prior to the development of cone-beam computed tomography (CBCT), surgical pre-evaluation consisted of the clinical exam and periapical and/or panoramic radiographs. These radiographs provide an estimate of the location of the root end and its proximity to vital structures; however, due to distortion and overlap, true positioning cannot be assessed by these two-dimensional images. Radiographic studies on healing

following surgery have been done for decades with two-dimensional radiography and early studies by Rud and Moller (1972) developed the classifications of healing after surgery, which are complete, incomplete, uncertain, and unsatisfactory. These classifications depended on radiographic findings, histology, and patient symptoms and have been used in nearly all radiographic studies of healing after surgery. Recently, additional classifications have been introduced to account for the third dimension that can be analyzed on cone-beam computed tomography.

CBCT was introduced to the dental world in the early 2000s and has recently become a common imaging modality for the assessment of dental and apical tissues prior to endodontic surgery. Molar and premolar roots are often in close proximity to vital structures such as the inferior alveolar nerve in the mandible and the maxillary sinus in the maxilla, which can present a challenge in surgical cases (von Arx 2013, von Arx 2014). With the use of CBCT, the distance between the root apex and other structures can be measured accurately making pre-surgical planning easier and the surgical procedure more predictable.

CBCT has been shown to be more accurate in diagnosis as well. Bornstein (2011) found that 25.9% of apical lesions that were detected on CBCT were missed using conventional two-dimensional radiography. Similarly, Lofthag-Hansen (2007) found that CBCT provided additional diagnostic information compared to panoramic or digital two-dimensional radiography in thirty-two out of forty-six cases. This is especially important in the maxillary posterior region. This region of the oral cavity has multiple structures

that often overlap on two-dimensional radiographs and can block out pathology or mimic pathology when none is present.

The original periapical index was developed by Orstavik (1986) to classify lesion size on two-dimensional radiographs. With a new imaging modality with a third dimension visible, a new scale had to be developed to accurately classify apical lesions present. This scale is based on the size of the lesion on a scale of zero to five with subcategories of D and E representing destruction or expansion of the cortical plate, respectively (Estrela 2008).

When performing apical surgery, it is important to evaluate not only the tooth and the lesion but also the surrounding structures. In the case of the maxillary posterior area, one should evaluate the maxillary sinus for the presence of mucosal thickening near the effected root and the proximity of the root end and lesion to the sinus. This pre-operative three-dimensional evaluation makes presurgical planning easier and allows the operator to predict potential complications in advance, such as a sinus perforation. Bornstein (2012) found that the bone separating the root from the maxillary sinus was usually thicker in patients with lesions and the sinus was more likely to appear healthy in patients without lesions. Maxillary posterior tooth roots can also frequently extend into the maxillary sinus and Pagin (2013) found on a random sample of CBCT scans that 35.9% (216/601) of maxillary posterior tooth roots were abutting up against the sinus wall or in the sinus with 14.3% (86/601) of roots protruding into the sinus. Pagin (2013) found that roots of the maxillary second premolar abut or extend into the sinus 11.6% of the time and for maxillary first molars this number increases to

31.9%. The study also found that the mesiobuccal root of the first molar, which is the root most likely to undergo a surgical procedure, is located in or up against the sinus 8.7% of the time and in second molars, the mesiobuccal root is found in these locations 22.2% of the time. These findings suggest that a surgical procedure in this area is likely to involve the maxillary sinus. However, CBCT is no better than conventional two-dimensional radiography for determining the histologic diagnosis of a lesion (Bornstein 2015). The best way to diagnose a periapical lesion is histologically.

The ability to effectively plan for apical surgery pre-operatively is beneficial to the patient as well. The use of CBCT pre-operatively compared to conventional radiography does not affect overall healing after surgery. However, three-dimensional surgical planning allows for decreased chair time for the patient and a lower incidence of sinus perforation (Kurt 2014). In fact, Ee et al (2014) found that practitioners altered their treatment plan 62% of the time when presented with a CBCT instead of periapical radiographs only. During surgical treatment planning of a case, evaluation of the maxillary sinus itself is also important. Conditions of the maxillary sinus can affect the maxillary posterior teeth and vice versa. Maillet et al (2011) found that maxillary sinusitis was eleven times more likely to be associated with molars than premolars and that a dental etiology for sinusitis always coincided with a disruption of the cortical bone of the sinus floor.

CBCT can also be used as a way of evaluating healing of a periapical lesion after treatment. While there may be slightly more radiation exposure for the patient, in certain areas where periapical radiographs are especially challenging for diagnosis such

as the maxillary posterior, it may be more beneficial to evaluate healing by recall CBCT scans. In a comparison between two- and three-dimensional radiographs taken at a one-year follow-up to evaluate healing, von Arx (2015) found that almost one third of cases appeared worse on CBCT than in a periapical radiograph. CBCT was shown to be beneficial in evaluating healing of lesions (Kaya 2012).

III. MATERIALS & METHODS

A. Study Design

The aim of the study was to evaluate the outcome of endodontic microsurgery on maxillary posterior teeth with or without a sinus perforation and determine the effect of a sinus perforation on overall healing after surgery. To carry out the objective, a retrospective study was designed. The study design was submitted to the UIC IRB for approval and it was determined the study did not involve human subjects and did not require IRB approval.

All CBCT scans were previously taken at a local endodontic specialty practice between January 1, 2011 and July 15, 2015. All Images were obtained using a Kodak 9000 3D extra-oral imaging system (Kodak Dental Systems, Atlanta, GA) using a limited field of view (5cm x 5cm) with a voxel size of 76 microns. All pre-operative CBCT scans taken for purposes of endodontic microsurgery on maxillary posterior teeth with at least a 6-month post-operative recall scan were included in this study.

Inclusion criteria for the study were permanent maxillary premolars and first and second molars referred for endodontic microsurgery on patients aged 18 years and older. All CBCT scans must have been taken between January 1, 2011 and July 15, 2015. Both the pre-operative and post-operative recall scans must be of high diagnostic value in all three dimensions. The pre-operative scan must show the presence of an endodontically treated tooth, which may be associated with a periapical radiolucency and/or have symptoms requiring endodontic microsurgery. Exclusion criteria were as

follows: non-diagnostic CBCT scans, and the absence of 6 month or greater post-operative recall scans.

B. Evaluation of CBCT scans

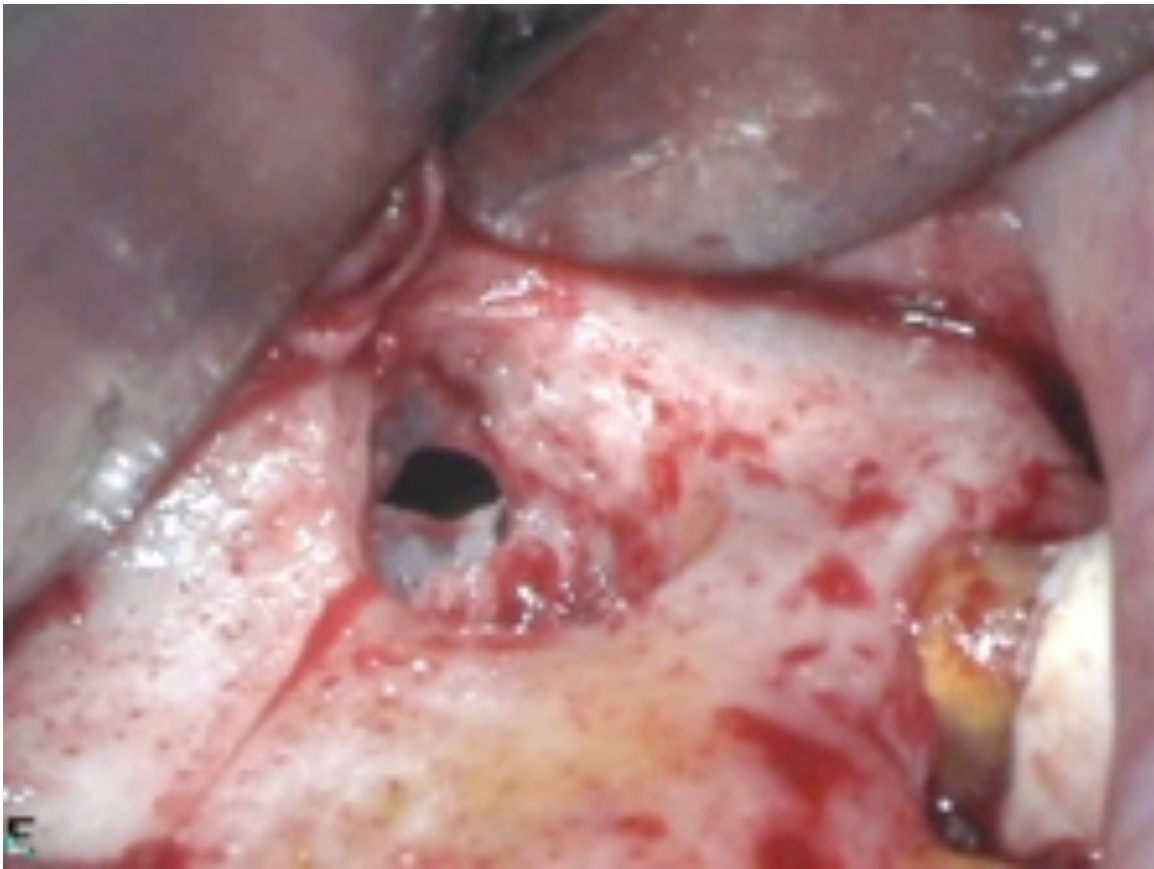Prior to evaluation, all CBCT scans meeting the inclusion criteria were gathered and de-identified. A unique code number was assigned to each scan and its recall to eliminate all patient identifiers. The code numbers were then placed in a random order for evaluation. All scans were evaluated using the CBCT computer software, either Carestream (Carestream Dental LLC, Atlanta, GA) or Invivo5 (Anatomage Medical, San Jose, CA). Each image was evaluated in all three dimensions, axial, coronal, and sagittal, for pre-operative lesion size using the CBCT PAI scale developed by Estrela (2008). The CBCT PAI scale runs from zero to five based on lesion diameter and has subcategories to denote expansion or lack of cortical plate. The corresponding post-operative recall scan was also evaluated using the CBCT PAI scale to determine if the lesion was healed, healing, or unhealed. All images were evaluated by two second-year endodontic residents and a board-certified endodontist. When evaluators were not in agreement on the CBCT PAI score, the image was discussed until agreement was reached. A case was considered healed when the CBCT PAI score on recall was zero. Healing for the purposes of this study was defined as a lower CBCT PAI score post-operatively compared to the pre-operative score. An unhealed case had a CBCT PAI score that was the same or larger than the pre-operative score. The CBCT PAI score was determined by aligning the three views (axial, coronal, and sagittal) on the center of the periapical lesion and

using the measuring tool in the CBCT software to measure the diameter at the greatest point.

C. Data Collection

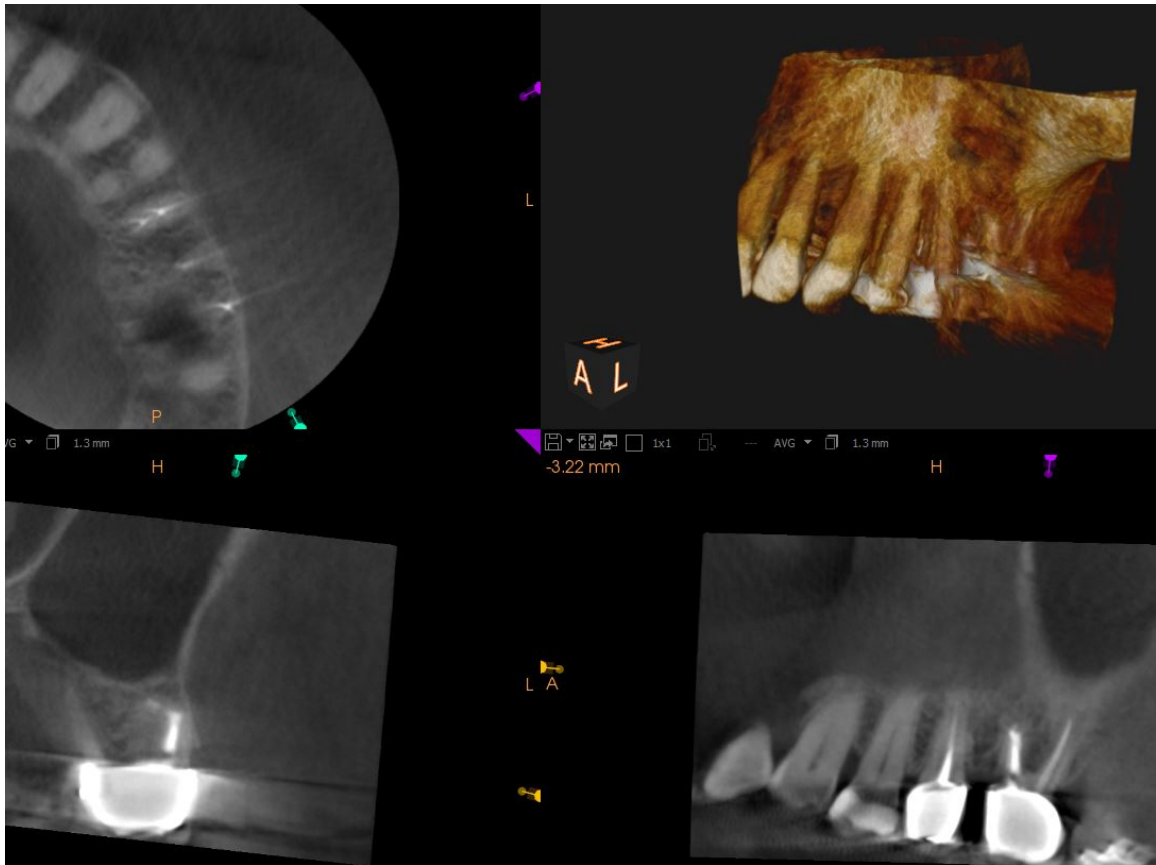
The date of the pre-operative and post-operative scans was recorded for all included cases and the length of the recall in months was determined. The gender and age group (under or over 50 years of age) were recorded for each case. The tooth number, tooth type, and root(s) involved were also recorded; two roots that were fused were counted as one. Both the pre-operative and post-operative CBCT PAI score was recorded for each root. The presence or absence of sinus involvement during surgery was recorded. For the purposes of this study, sinus involvement was defined as follows: the microsurgical procedure will cause a perforation into the maxillary sinus. Perforation of the sinus is determined more by the proximity of the tooth root to the maxillary sinus than by the size of the periapical lesion. It is possible to have a very large lesion without a sinus perforation or a small lesion with a sinus perforation. The presence or absence of bone graft placement during surgery was also noted.

FIGURE 1: SINUS PERFORATION



Courtesy of Dr. M. Fayad

FIGURE 2 – Healed tooth #3 after surgery with sinus perforation



Courtesy of Dr. M. Fayad

IV. STATISTICAL ANALYSIS

The data was analyzed using the chi-square test (SPSS for Windows, Version 22, SPSS Inc.,). Significance was set at $p < 0.05$ for all statistical tests. A power calculation was also completed.

V. RESULTS

CBCT scans from 33 surgical patients for 42 roots were included in this study. 19 roots had a sinus perforation during surgery and 23 roots had no perforation. Recall time ranged from 6 months to 30 months post-operatively with an average recall time of 13.8 months. The chi-square test was used to determine the effect of patient age and sex and the use of a bone graft during surgery. Age and sex of the patient did not have a significant effect on healing with p values of $p=0.825$ and $p=0.302$, respectively. Placement of a bone graft during surgery also did not have a significant effect on healing, $p=0.328$ (see Table I).

TABLE I: NON-SIGNIFICANT FACTORS

| Factor | p-value |
|-----------------------|----------------|
| Sex | 0.302 |
| Age | 0.825 |
| Bone Graft Use | 0.328 |

The overall failure rate of apical surgery by tooth in this study was 21.2% and by root was 24% (see Table II). There was a significant difference in healing between the group with a sinus perforation during surgery and the group without sinus perforation

($p < 0.05$). When comparing the healed, healing and unhealed groups, the significant difference was between the healing groups (see Table III). When healed and healing were combined into one group, there was no significant difference between the sinus perforation and no sinus perforation groups ($p = 0.267$) (see Table IV). For the purposes of this study, healed was classified as a PAI score of zero on the recall CBCT and healing was classified as a lower PAI score on recall compared to the pre-operative PAI score. Not healed cases were those that had the same PAI score or a larger PAI score on the recall CBCT compared to the pre-operative PAI score.

TABLE II: PERCENTAGE HEALING BY TOOTH AND BY ROOT

| | Total (by tooth) | Total (by root) |
|-------------------|-------------------------|------------------------|
| Healed | 20/33 (60.6%) | 24/42 (57%) |
| Healing | 6/33 (18.2%) | 8/42 (19%) |
| Not Healed | 7/33 (21.2%) | 10/42 (24%) |

TABLE III: HEALING VS. SINUS PERFORATION BY ROOT

| | SINUS PERFORATION | NO SINUS PERFORATION |
|-------------------|--------------------------|-----------------------------|
| HEALED | 9/19 (47.4%) | 15/23 (65.3%) |
| HEALING | 7/19 (36.8%) | 1/23 (4.3%) |
| NOT HEALED | 3/19 (15.8%) | 7/23 (30.4%) |

TABLE IV: COMBINED HEALED AND HEALING VS. SINUS PERFORATION

| | SINUS PERFORATION | NO SINUS PERFORATION |
|-------------------------|--------------------------|-----------------------------|
| HEALED + HEALING | 16/19 (84.4%) | 16/23 (69.6%) |
| NOT HEALED | 3/19 (15.8%) | 7/23 (30.4%) |

VI. DISCUSSION

The aim of this study was to determine the outcome of endodontic microsurgery (root-end surgery) with or without sinus perforation during surgery. This study was retrospective in nature.

The methodology used in this study is similar to retrospective studies evaluating healing after endodontic surgery using two-dimensional radiography (Rud 1972). However, for this study, complete and incomplete healing were kept separate and labeled as healed (complete) and healing (incomplete) and uncertain and unsatisfactory healing were grouped together as not healed cases. As far as we know, this the first study looking at the effect of proximity of vital structures on healing following endodontic microsurgery by examination of CBCT scans. All cases analyzed had both a pre-operative CBCT scan and a recall scan of at least 6 months post-operatively. Healing after endodontic microsurgery was evaluated using CBCT due to its improved diagnostic value (Lofthag-Hansen 2007). CBCT was also chosen as the recall evaluation modality because of the more accurate evaluation of healing post-operatively (Kaya 2012).

In this study, comparison of cases with a sinus perforation during surgery and those without sinus perforation was done and healing was evaluated. There was a statistically significant difference, which was seen in the “healing” group. Although the sample size in this study was small, this difference could be due to the fact that a lesion that causes a sinus perforation during apical surgery could be thought of as being similar to a through-and-through lesion. Tsesis (2011) showed in a systematic review that guided tissue regeneration could be beneficial in through-and-through lesions to aid in

healing. Guided tissue regeneration, or bone grafting, is more challenging in cases of sinus perforation and cannot always be done depending on the size and location of the perforation. Management of a sinus perforation is dependent on many factors, including size, location, and operator preference. Pecora (1995) showed that no use of guided tissue regeneration in large lesions tends to slow the healing process. The slower healing process for large and through-and-through lesions would explain the larger number of cases classified as healing in the sinus perforation group.

A recent study by von Arx (2016) discusses a new scale for evaluation of healing on CBCT after root-end surgery. This study suggests healing should be evaluated in three different areas and scored from zero to two in each section. Examination of the R-plane evaluates healing at the resected root surface. The A score is determined by evaluating the amount of bone formation in the apical area and the C score is determined by examining the amount of reformation of the cortical plate in the area of surgery. The B score was achieved by assessing the A and C indices together. This evaluation scale was not yet presented at the time this study was initiated. Therefore, future evaluations should be completed using the von Arx (2016) RACB scores for healing on CBCT.

Although no studies have investigated healing after endodontic microsurgery with proximity to vital structures, the results of this study are consistent with other studies in terms of healing time and overall healing. From the results of this study, it can be gathered that a perforation into the maxillary sinus during endodontic microsurgery does not affect the overall success rate for surgery.

VII. CLINICAL RELEVANCE AND LIMITATIONS

The study was completed using de-identified CBCT scans taken for actual patients undergoing endodontic microsurgery and recall scans.

Limitations of this study include the small sample size. However, even in a busy private practice setting, a root-end surgery on a maxillary posterior tooth with a sinus perforation during surgery is not a common occurrence. Along with this, the minimum recall time required in this study was 6 months. A more accurate recall time to evaluate cases of root-end surgery has been shown to be 12 months (Rud 1972). Therefore, it is possible that some healed cases may still have grafting material present in the surgical site and would be an inaccurate representation of true healing. Another limitation is that one operator completed all of the surgical procedures. While this somewhat standardizes the surgical procedure, one operator is a limitation because the operator is a highly skilled surgeon, which could make the success rates artificially high. Another limitation that should be considered is recall bias. Recall bias states that those patients who return for recall are more often those who are having symptoms or problems related to the tooth. This can affect the outcome and artificially increase the failure rate. One final limitation is that there was no standardized surgical protocol or protocol for the management of a sinus perforation due to the retrospective nature of the study. However, all surgeries were completed by one operator, which means the protocol may have changed slightly over time but is likely to have remained relatively constant.

VIII. FUTURE RESEARCH

The results of this study suggest future studies with a larger sample size are needed. Also, a recall period of a minimum of twelve months instead of six months would be beneficial because Maddalone et al (2003) showed that a recall period of at least twelve months is necessary to effectively evaluate healing.

Another consideration is the age of the patient. While in a private practice setting endodontic microsurgery is rarely completed on patients under 25 years of age, the patient population in a dental school setting is very different and frequently surgical patients are in a younger age group. In a rabbit study done by Bahadir in 2008, sinus surgery was completed on one side and not the other and sinus development following surgery was compared to normal sinus development. They found that the sinus which had surgery showed significantly hindered growth and development compared to the normal side (Bahadir 2008). Further studies should be done to help determine if this correlates to humans and, if in younger patients, the better treatment option would be nonsurgical retreatment to allow for complete development of the face prior to surgery.

IX. CONCLUSIONS

In conclusion, this study showed that a sinus perforation during endodontic microsurgery does not affect the overall outcome of the surgical procedure. Also, other variable factors such as age and sex may not affect healing after surgery in the maxillary posterior but this cannot be extrapolated to other areas of the mouth from the results of this study. Further research is needed to determine if a perforation into the maxillary sinus affects healing time after endodontic microsurgery.

X. CITED LITERATURE

AAE and AAOMR Joint Position Statement. *Journal of Endodontics*. 41.9 (2015): 1393-1396.

Abedi HR, et al. Effects of ultrasonic root-end cavity preparation on the root apex. *Oral Surgery, Oral Medicine, Oral Pathology, Oral Radiology, and Endodontology* 80 (1995): 207-2013

von Arx T, et al. Agreement between 2D and 3D radiographic outcome assessment one year after periapical surgery. *International Endodontic Journal* (2015).

von Arx T, et al. Evaluation of New Cone Beam Computed Tomographic Criteria for Radiographic Healing Evaluation after Apical Surgery: Assessment of Repeatability and Reproducibility. *Journal of Endodontics* 42.2 (2016): 236-242.

von Arx T, et al. Five-year Longitudinal Assessment of the Prognosis of Apical Microsurgery. *Journal of Endodontics* 38.5 (2012): 570-9.

von Arx T, et al. Location and Dimensions of the Mental Foramen: A Radiographic Analysis by Using Cone-beam Computed Tomography. *Journal of Endodontics* 39.12 (2013): 1522-528.

von Arx, T, Fodich I, Bornstein MM. "Proximity of Premolar Roots to Maxillary Sinus: A Radiographic Survey Using Cone-beam Computed Tomography." *Journal of Endodontics* 40.10 (2014): 1541-548.

Baek SH, et al. Periapical bone regeneration after endodontic microsurgery with three different root-end filling materials: Amalgam, SuperEBA, and Mineral trioxide aggregate. *Journal of Endodontics* 36.8 (2010): 1323-1325.

Bahadir O, et al. The Effect of Maxillary Sinus Surgery on Its Development. *Acta Otolaryngologica* 128.5 (2008): 551-55.

Beling KL, et al. Evaluation for Cracks Associated with Ultrasonic Root-End Preparation of Gutta-Percha Filled Canals. *Journal of Endodontics* 23.5 (1997): 323-326.

Bornstein MM, et al. An Analysis of Frequency, Morphology, and Locations of Maxillary Sinus Septa Using Cone Beam Computed Tomography. *The International Journal of Oral & Maxillofacial Implants* 31.2 (2016): 280-287.

Bornstein MM, et al. Characteristics and Dimensions of the Schneiderian Membrane and Apical Bone in Maxillary Molars Referred For Apical Surgery: A Comparative Radiographic Analysis Using Limited Cone Beam Computed Tomography. *Journal of Endodontics* 38.1 (2012): 51-57.

Bornstein MM, et al. Comparison between Radiographic (2-dimensional and 3-dimensional) and Histologic Findings of Periapical Lesions Treated with Apical Surgery. *Journal of Endodontics* 41.6 (2015): 804-11.

Bornstein MM, et al. Comparison of Periapical Radiography and Limited Cone-Beam Computed Tomography in Mandibular Molars for Analysis of Anatomical Landmarks before Apical Surgery. *Journal of Endodontics* 37.2 (2011): 151-57.

Chong BS, Pitt Ford TR, Hudson MB. A prospective clinical study of Mineral Trioxide Aggregate and IRM when used as root-end filling materials in endodontic surgery. *International Endodontic Journal* 36.8 (2003): 520-526.

Dorn SO, Gartner AH. Retrograde filling materials: A retrospective success-failure study of amalgam, EBA, and IRM. *Journal of Endodontics* 16.8 (1990); 16: 391-393.

Ee J, Fayad MI, Johnson BR. Comparison of endodontic diagnosis and treatment planning decisions using cone-beam volumetric tomography versus periapical radiography. *Journal of Endodontics* 40.7 (2014): 910-916.

Estrela C, et al. A New Periapical Index Based on Cone Beam Computed Tomography. *Journal of Endodontics* 34.11 (2008): 1325-331.

Estrela C, et al. Accuracy of Cone Beam Computed Tomography and Panoramic and Periapical Radiography for Detection of Apical Periodontitis. *Journal of Endodontics* 34.3 (2008): 273-79.

Gilheany PA, et al. Apical dentin permeability and microleakage associated with root end resection and retrograde filling. *Journal of Endodontics* 20.1 (1994): 22-26.

Goiato MC, et al. Longevity of Dental Implants in Type IV Bone: A Systematic Review. *International Journal of Oral and Maxillofacial Surgery* 43.9 (2014): 1108-1116.

Gutmann JL. Surgical Endodontics: Past, Present, and Future. *Endodontic Topics* 30 (2014): 29-43.

Kaya S, et al. Measuring Bone Density in Healing Periapical Lesions by Using Cone Beam Computed Tomography: A Clinical Investigation. *Journal of Endodontics* 38.1 (2012): 28-31.

Kurt SN, et al. Outcomes of Periradicular Surgery of Maxillary First Molars Using a Vestibular Approach: A Prospective, Clinical Study With One Year of Follow-Up." *Journal of Oral and Maxillofacial Surgery* 72.6 (2014): 1049-061.

Lemagner F, et al. Prevalence of Apical Bone Defects and Evaluation Of Associated Factors Detected with Cone-beam Computed Tomographic Images. *Journal of Endodontics* 41.7 (2015): 1043-047.

de Lange J, et al. Ultrasonic root-end preparation in apical surgery: a prospective randomized study. *Oral Surgery, Oral Medicine, Oral Pathology, Oral Radiology, and Endodontology* 104.6 (2007): 841-845.

Lindeboom JAH, et al. A comparative prospective randomized clinical study of MTA and IRM as root-end filling materials in single-rooted teeth in endodontic surgery. *Oral Surgery, Oral Medicine, Oral Pathology, Oral Radiology, and Endodontology* 100.4 (2005): 495-500.

Lofthag-Hansen S, et al. Limited Cone-beam CT and Intraoral Radiography for the Diagnosis of Periapical Pathology. *Oral Surgery, Oral Medicine, Oral Pathology, Oral Radiology, and Endodontology* 103.1 (2007): 114-19.

Low KMT, et al. Comparison of Periapical Radiography and Limited Cone-Beam Tomography in Posterior Maxillary Teeth Referred for Apical Surgery. *Journal of Endodontics* 34.5 (2008): 557-62.

Maddalone M and Gagliani M. Periapical endodontic surgery: a 3-year follow-up study. *International Endodontic Journal* 36.3 (2003): 193-198.

Maillet M, et al. Cone-beam Computed Tomography Evaluation of Maxillary Sinusitis. *Journal of Endodontics* 37.6 (2011): 753-57.

Ng YL, et al. Outcome of primary root canal treatment: systematic review of the literature – Part 2. Influence of clinical factors. *International Endodontic Journal* 41.1 (2008): 6-31.

Orstavik D, et al. The periapical index: A scoring system for radiographic assessment of apical periodontitis. *Dental Traumatology* 2.1 (1986): 20-34.

Pagin O, et al. Maxillary Sinus and Posterior Teeth: Accessing Close Relationship by Cone-Beam Computed Tomographic Scanning in a Brazilian Population. *Journal of Endodontics*. 39.6 (2013): 748-751.

Patel S. New Dimensions in Endodontic Imaging: Part 2. Cone Beam Computed Tomography. *International Endodontic Journal* 42.6 (2009): 463-75.

Pecora G, et al. The guided tissue regeneration principle in endodontic surgery: one-year postoperative results of large periapical lesions. *International Endodontic Journal* 28 (1995): 41-46.

Perrin P, Neuhaus KW, Lussi A. The impact of loupes and microscopes on vision in endodontics. *International Endodontic Journal* 47.5 (2014): 425-429.

Rosen E, et al. The Diagnostic Efficacy of Cone-beam Computed Tomography in Endodontics: A Systematic Review and Analysis by a Hierarchical Model of Efficacy. *Journal of Endodontics* 41.7 (2015): 1008-014.

Rud J, Andreasen JO, and Moller JEJ. A follow-up study of 1,000 cases treated by endodontic surgery. *International Journal of Oral Surgery* 1.4 (1972): 215-228.

Rud J, Andreasen JO, and Moller JEJ. Radiographic criteria for the assessment of healing after endodontic surgery. *International Journal of Oral Surgery* 1.4 (1972): 195-214.

Setzer FC, et al. Outcome of Endodontic Surgery: A Meta-analysis of the Literature– Part 1: Comparison of Traditional Root-end Surgery and Endodontic Microsurgery. *Journal of Endodontics* 36.11 (2010): 1757-1765.

Setzer FC, et al. Outcomes of Endodontic Surgery: A Meta-analysis of the Literature – Part 2: Comparison of Endodontic Microsurgical Techniques with and without the Use of Higher Magnification. *Journal of Endodontics* 38.1 (2012): 1-10.

Taschieri S, et al. Endoscopic Minimally Invasive Management of a Periradicular Lesion Invading the Maxillary Sinus. *Journal of Oral Science* 53.4 (2011): 533-38.

Tsesis I, et al. Effect of Guided Tissue Regeneration on the Outcome of Surgical Endodontic Treatment: A Systematic Review and Meta-analysis. *Journal of Endodontics* 37.8 (2011): 1039-1045.

Tsesis I, et al. Outcomes of Surgical Endodontic Treatment Performed by a Modern Technique: An Updated Meta-analysis of the Literature. *Journal of Endodontics* 39.3 (2013): 332-339.

Walivaara D, et al. Periapical Tissue Response After Use of Intermediate Restorative Material, Gutta-Percha, Reinforced Zinc Oxide Cement, and Mineral Trioxide Aggregate as Retrograde Root-End Filling Materials: A Histologic Study in Dogs. *Journal of Oral and Maxillofacial Surgery* 70.9 (2012): 2041-2047.

Waplinton M, et al. Incidence of Root Face Alteration after Ultrasonic Retrograde Cavity Preparation. *Oral Surgery, Oral Medicine, Oral Pathology, Oral Radiology, and Endodontology* 83.3 (1997): 387-392.

Yazdi PM, et al. Dentine-bonded resin composite (Retroplast) for root-end filling: A prospective clinical and radiographic with a mean follow-up period of 8 years. *International Endodontic Journal* 40 (2007): 493-503.

VITA

NAME: Lauren Marie Allegretti

EDUCATION: B.S., Molecular and Cellular Biology, University of Illinois at Urbana-Champaign, Champaign, Illinois, 2010

D.D.S., University of Illinois at Chicago College of Dentistry, Chicago, Illinois, 2014

TEACHING: Teaching Assistant, General Chemistry, Chemistry Department, University of Illinois at Urbana-Champaign, Champaign, Illinois, 2009-2010

Teaching Assistant, Removable Partial Denture Course, Department of Restorative Dentistry, University of Illinois at Chicago College of Dentistry, Chicago, Illinois, 2013

Teaching Assistant, Pre-Doctoral Technique Course, Department of Endodontics, University of Illinois at Chicago College of Dentistry, Chicago, Illinois, 2014

Resident Clinical Instructor, Department of Endodontics, University of Illinois at Chicago College of Dentistry, Chicago, Illinois, 2015-2016

PROFESSIONAL MEMBERSHIP: American Association of Endodontists
American Dental Association
Illinois State Dental Society
Chicago Dental Society
Edgar D. Coolidge Endodontic Study Club